

**Clinical Image**

# Millian's ear sign: Bilateral ear erythema

**Roberto Benavides Arenas<sup>1\*</sup> and Juan Camilo Jaramillo<sup>2</sup>**

<sup>1</sup>Hospital Universitario San Vicente Fundacion, Medellin, Colombia

<sup>2</sup>Residente Medicina Interna, Universidad de Antioquia, Medellín, Colombia

A 79 years old woman presented with one-day history of pain, redness, pain and swelling without discharge in her left ear, later her right ear started with the same symptoms as in her contralateral ear spreading around the scalp and the forehead (Figure 1), she denied fever, or other constitutional symptoms.

Her medical record was remarkable for controlled type 2 diabetes, primary hypertension. Physical examination revealed bilateral signs of auricular inflammation spreading to the right side of the forehead and mastoid.

The patient was treated with intravenous clindamycin during 7 days with full resolution (Figure 2).

Milian's ear sign differentiate cellulitis and erysipelas, the reason is that cellulitis compromises deep dermis and subcutaneous tissue and erysipelas compromises the epidermis and superficial lymphatics, the former structures are absent in the pinna, so cellulitis cannot explain an infection of soft tissue in this latter structure of the ear [1,2].

**More Information**

**\*Address for Correspondence:**

Roberto Benavides Arenas, Hospital Universitario San Vicente Fundacion, Medellin, Colombia, Tel: +573235884615; Email: Raroben1319@gmail.com

**Submitted:** March 01, 2021

**Approved:** March 08, 2021

**Published:** March 09, 2021

**How to cite this article:** Arenas RB, Jaramillo JC. Millian's ear sign: Bilateral ear erythema. J Clin Med Exp Images. 2021; 5: 001-001.

**DOI:** 10.29328/journal.jcmei.1001017

**ORCID:** orcid.org/0000-0002-2401-7638

**Copyright:** © 2021 Arenas RB, et al. This is an open access article distributed under the Creative Commons Attribution License, which permits unrestricted use, distribution, and reproduction in any medium, provided the original work is properly cited.

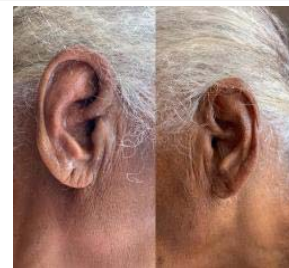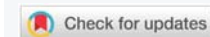


Figure 2

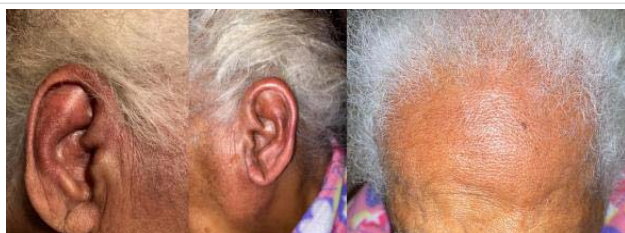

Figure 1

## References

1. Suzuki K, Otsuka H. Bilateral Milian's Ear Sign of Erysipelas. Intern Med. 2017; 56: 2381-2382. **PubMed:** <https://pubmed.ncbi.nlm.nih.gov/28794379/>
2. Matsuura H, Senoo A, Saito M, Hamanaka Y. Milian's ear sign. QJM. 2018; 111: 415. **PubMed:** <https://pubmed.ncbi.nlm.nih.gov/29309645/>